
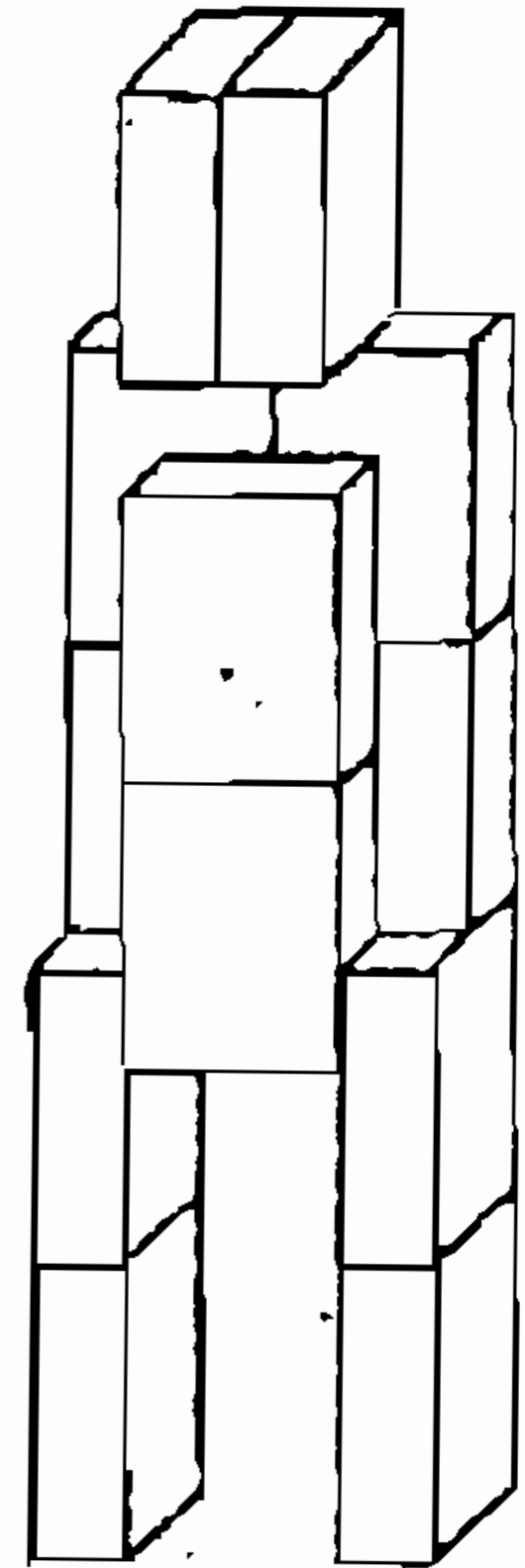


P1, sagittal plane



Anterior

Posterior

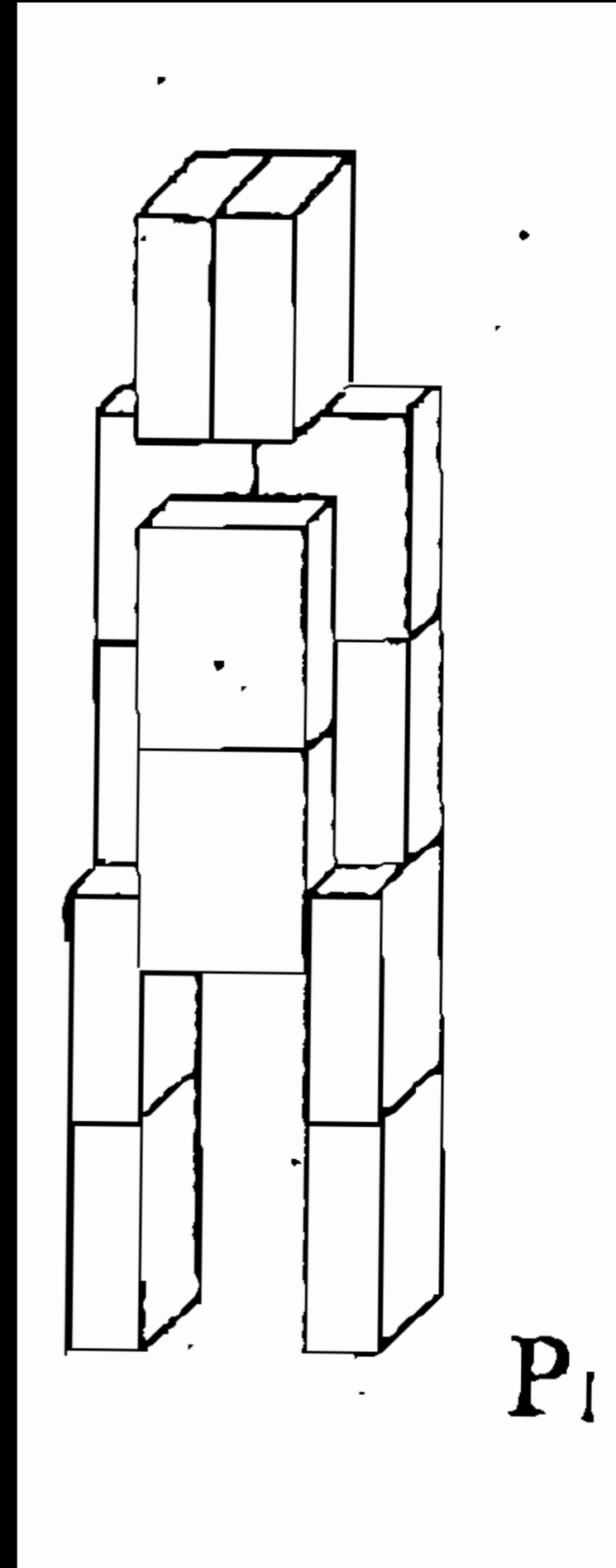
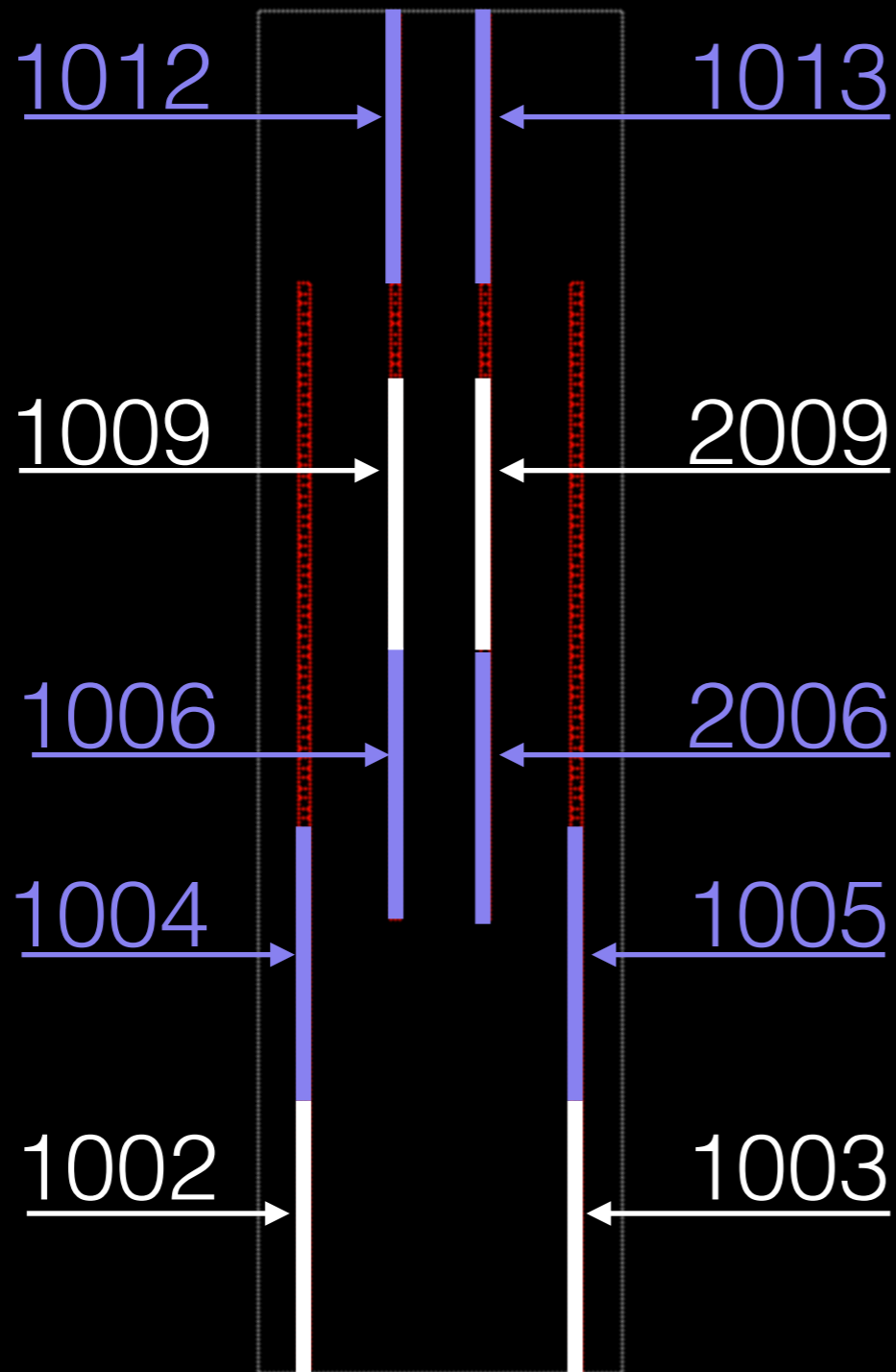


P1

P1 anterior

Right

Left



P1 posterior

Right

Left

